UNITED STATES PATENT AND TRADEMARK OFFICE

UNITED STATES DEPARTMENT OF COMMERCE
United States Patent and Trademark Office
Address: COMMISSIONER FOR PATENTS
P.O. Box 1450
Alexandria, Virginia 22313-1450
www.uspto.gov

APPLICATION NO.	FILING DATE	FIRST NAMED INVENTOR	ATTORNEY DOCKET NO.	CONFIRMATION NO.
11/478,400	06/28/2006	Ramarao S. Chatlapalli	AM101939	7086

25291 7590 01/24/2013
WYETH LLC
PATENT LAW GROUP
5 GIRALDA FARMS
MADISON, NJ 07940

EXAMINER
SZNAIDMAN, MARCOS L

ART UNIT	PAPER NUMBER
1628	

NOTIFICATION DATE	DELIVERY MODE
01/24/2013	ELECTRONIC

Please find below and/or attached an Office communication concerning this application or proceeding.

The time period for reply, if any, is set in the attached communication.

Notice of the Office communication was sent electronically on above-indicated "Notification Date" to the following e-mail address(es):

~IPGSMadisonDocketing@pfizer.com

UNITED STATES PATENT AND TRADEMARK OFFICE

BEFORE THE PATENT TRIAL AND APPEAL BOARD

Ex parte RAMARAO S. CHATLAPALLI, ARWINDER S. NAGI, and LAWRENCE VAN PELT

Appeal 2011-004447
Application 11/478,400
Technology Center 1600

Before ERIC GRIMES, FRANCISCO C. PRATS, and SHERIDAN K. SNEDDEN, *Administrative Patent Judges*.

SNEDDEN, *Administrative Patent Judge*.

DECISION ON APPEAL

This is an appeal under 35 U.S.C. § 134 involving claims to pharmaceutical compositions. The Examiner has rejected the claims as obvious. We have jurisdiction under 35 U.S.C. § 6(b). We affirm.

STATEMENT OF THE CASE

Claims 1-50, 64, 73 and 74 are on appeal. Claim 1 is representative and reads as follows:

> 1. A pharmaceutical composition comprising a core and at least one coating; wherein the core comprises conjugated estrogens; and the coating comprises bazedoxifene, or a pharmaceutically acceptable salt thereof.

The sole rejection before us for review is the Examiner's rejection of claims 1-50, 64 and 73-74 under 35 U.S.C. § 103(a) as being unpatentable over Komm #1,[1] Komm #2,[2] Barcomb,[3] and Miller.[4]

I.

Issue

The Examiner finds that bazedoxifene and medroxyprogesterone acetate (MPA) are functional equivalents as both compounds are known to antagonize the unwanted effects caused by the administration of estrogen, that is, the stimulation of uterus cell proliferation (Ans. 10). Specifically, the Examiner finds that Komm #1 discloses that "[bazedoxifene] was effective in counteracting the negative effects of the administration of [conjugated estrogens (Premarin®)] to the uterus" (Ans. 9). The Examiner finds that Miller discloses that "the hyperplastic (i.e. cell proliferation) action of estrogen on uterine tissue can be successfully opposed by the

---

[1] Komm et. al., American Society for Bone and Mineral Research (2003) Abstract SU385.
[2] Komm et al., US 2004/0063692 A1, published Apr. 1, 2004.
[3] Barcomb, US 5,547,948, issued Aug. 20, 1996.
[4] Miller et al., "Design, Synthesis, and Preclinical Characterization of Novel Highly Selective Indole Estrogens," 44 J. MED. CHEM. 1654-1657 (2001).

coadministration of progestin" (Ans. 10, citing Miller at p. 1654, left col.), and that Barcomb discloses "a compressed tablet, wherein the tablet core contains a unit does [sic] of Premarin and a coating of medroxyprogesterone acetate (MPA, a known progestin)" (Ans. 5).

In reaching a conclusion of obviousness, the Examiner finds that

> it would have been *prima facie* obvious for a person of ordinary skill in the art to make a tablet formulation of the mixture taught by [Komm #1] (bazedoxifene and Premarin) since [Komm #2] and Barcomb already teach tablet formulations of bazedoxifene and Premarin respectively, and further Barcomb teaches a core with Premarin and a coating with MPA, and replace one functional equivalence (MPA) with another (bazedoxifene), since both: bazedoxifene and MPA are known to counteract the side effects of estrogens (like Premarin) against breast and uterine tissues, thus resulting in the practice of claims 1-3 with a reasonable expectation of success.

(Ans. 5.)

Appellants contend that "there is no suggestion in [Barcomb] that MPA is interchangeable, equivalent or could be substituted by bazedoxifene to achieve Appellants' claimed composition" and thus, "based on the facts, that Office is incorrect in its reliance on the limited teaching of the Barcomb" (App. Br. 11). Appellants further contend that "[a]ny reading of the reference cited would not lead a person of ordinary skill in the art to substitute MPA for bazedoxifene" because the cited art "does not disclose or suggest that MPA is interchangeable, equivalent or could be substituted by bazedoxifene" (*id.* at 13.)

The issue presented is:

Does the evidence of record support the Examiner's conclusion that the cited prior art renders claim 1 obvious?

Findings of Fact

The following findings of fact ("FF") are supported by a preponderance of the evidence of record.

FF1. Komm #1 discloses a combination of bazedoxifene acetate and Premarin® (conjugated estrogens) for the treatment and prevention of osteoporosis in order to provide "a balanced, acceptable 'estogenic' profile" (*See* Komm #1, Abst.).

FF2. Komm #1 discloses that "CE [conjugated estrogens] was combined with BZA [bazedoxifene] to determine the efficacy of BZA to antagonize the CE stimulation of the uterus" (*id.*). Komm #1 discloses that the uteri from animals co-dosed with bazedoxifene and conjugated estrogens "were not different from . . . untreated controls" (*id.*).

FF3. Miller discloses that the "hyperplastic action of estrogen on uterine tissue can be successfully opposed by the coadministration of a progestin" (Miller p. 1654, left col.).

FF4. Barcomb teaches the controlled release of a hormonal steroid from the sugar coating of a tablet (Barcomb col. 1, l. 66, to col. 2, l. 35) and that "[e]xamples of hormonal steroids suitable for incorporation into the sugar coating formulations of this invention include, medroxyprogesterone acetate" (Barcomb, col. 2, ll. 38-40).

FF5. Barcomb teaches a formulation of Premarin® (a naturally occurring conjugated estrogen) in a compressed tablet, where the tablet core

contains a unit dose of Premarin®, and where the tablet has a sugar coat containing medroxyprogesterone acetate (MPA). (Barcomb col. 6, ll. 17-29.)

FF6. Kumasaka[5] teaches that MPA is a progestin that provides "slight[] endometrial protection against the hyperplastic response" of the estrogen-primed, ovariectomized rat. (Kumasaka, Abst.)

Principles of Law

Substituting one art recognized equivalent for another is obvious. *See KSR Int'l Co. v. Teleflex lnc*, 550 U.S. 398, 416 ("The combination of familiar elements according to known methods is likely to be obvious when it does no more than yield predictable results"); *In re Fout*, 675 F.2d 297, 301 (CCPA 1982).

Analysis

MPA was a known progestin at the time of filing of this application (FF6). The preponderance of evidence on this record supports the Examiner's conclusion that bazedoxifene and progestins (such as MPA) are art recognized functional equivalents as both were known to oppose the stimulation of the uterus caused by the administration of estrogens (FF2 and FF3). This, in our view, presents strong evidence of obviousness in substituting MPA in the tablet disclosed by Barcomb with bazedoxifene to achieve the composition of claim 1. We are not persuaded by Appellants' arguments to the contrary.

---

[5] Kumasaka et al., "Effects of Various Forms of Progestin on the the Estrogen-Primed, Ovariectomized Rat," 41 Endocrine J. 161-169 (1994).

Although we agree that the prior art cited by the Examiner supports a prima facie case of obviousness, our reasoning further relies on Kumasaka to establish the fact that MPA is a progestin. For this reason we designate our decision a new ground of rejection to provide Appellants a full and fair opportunity to address this new evidence.

Conclusion of Law

The preponderance of the evidence of record supports the Examiner's conclusion that the cited prior art renders claim 1 obvious. Claims 2-50, 64, 73 and 74 fall with claim 1. 37 C.F.R. § 41.37(c)(1)(vii).

SUMMARY

We affirm the rejection of claims 1- 50, 64 and 73-74 under 35 U.S.C. § 103(a) as being unpatentable over Komm #1, Komm #2, Barcomb, and Miller. As our analysis varies from that of the Examiner, we designate our decision in this appeal a new ground of rejection.

TIME PERIOD FOR RESPONSE

This decision contains a new ground of rejection pursuant to 37 C.F.R. § 41.50(b) (effective September 13, 2004, 69 Fed. Reg. 49960 (August 12, 2004), 1286 Off. Gaz. Pat. Office 21 (September 7, 2004)). 37 C.F.R. § 41.50(b) provides "[a] new ground of rejection pursuant to this paragraph shall not be considered final for judicial review."

37 C.F.R. § 41.50(b) also provides that Appellant, WITHIN TWO MONTHS FROM THE DATE OF THE DECISION, must exercise one of the following two options with respect to the new ground of rejection to avoid termination of the appeal as to the rejected claims:

(1) Reopen prosecution. Submit an appropriate amendment of the claims so rejected or new evidence relating to the claims so rejected, or both, and have the matter reconsidered by the Examiner, in which event the proceeding will be remanded to the Examiner. . . .

(2) Request rehearing. Request that the proceeding be reheard under § 41.52 by the Board upon the same record.

AFFIRMED, 37 C.F.R § 41.50(b)

lp

Notice of References Cited	Application/Control No. 11/478,400	Applicant(s)/Patent Under Reexamination CHATLAPALLI ET AL.	
	Examiner MARCOS SZNAIDMAN	Art Unit 1628	Page 1 of 1

U.S. PATENT DOCUMENTS

*		Document Number Country Code-Number-Kind Code	Date MM-YYYY	Name	Classification
	A	US-			
	B	US-			
	C	US-			
	D	US-			
	E	US-			
	F	US-			
	G	US-			
	H	US-			
	I	US-			
	J	US-			
	K	US-			
	L	US-			
	M	US-			

FOREIGN PATENT DOCUMENTS

*		Document Number Country Code-Number-Kind Code	Date MM-YYYY	Country	Name	Classification
	N					
	O					
	P					
	Q					
	R					
	S					
	T					

NON-PATENT DOCUMENTS

*		Include as applicable: Author, Title Date, Publisher, Edition or Volume, Pertinent Pages)
	U	Kumasaka et al., “Effects of Various Forms of Progestin on the the Estrogen-Primed, Ovariectomized Rat,” 41 Endocrine J. 161-169 (1994).
	V	
	W	
	X	

*A copy of this reference is not being furnished with this Office action. (See MPEP § 707.05(a).)
Dates in MM-YYYY format are publication dates. Classifications may be US or foreign.

Endocrine Journal 1994, **41** (2), 161–169

Effects of Various Forms of Progestin on the Endometrium of the Estrogen-Primed, Ovariectomized Rat

TAKAHIRO KUMASAKA, EIICHI ITOH, HIDEKI WATANABE, KEIKO HOSHINO, AKIRA YOSHINAKA AND NOBUHIDE MASAWA*

The Department of Obstetrics and Gynecology and
**the First Department of Pathology, Dokkyo University, Tochigi 321–02, Japan*

Abstract. Progestin supplementation has been advocated in estrogen treatment for postmenopausal women to avoid proliferation of the endometrium. In this study we investigated the morphologic and biochemical effects of progestins on the endometrium of estrogen primed, ovariectomized rats.

As the progestin derivatives, Allylestenol (AE), Norethisterone (NE), Danazol (DZ), Dydrogesterone (DG), Medroxyprogesterone acetate (MPA) and Cyproterone acetate (CPA), and as a anti-estrogen compound, Tamoxifen (TMX), were applied. To evaluate the effects of these different compounds on the endometrium, histologic studies and measurement of estrogen receptor concentrations were performed. When 19-nortestosterone groups, AE, DZ and NE, were orally administered to the conjugated equine estrogen (CE) treated, ovariectomized rats, the histologic pattern of the endometrium revealed rather a marked inhibition of hyperplasia induced by CE than a progestational response. Two of 3 of 17α-hydroxyprogesterone groups, DG and MPA, provided slightly endometrial protection against the hyperplastic response, but another one, CPA, did not have any inhibitory effect on the estrogenic stimulation of the endometrium. TMX was not capable of suppressing the endometrial hyperplasia caused by CE administration.

The average plasma concentrations of estradiol (E_2) were 82.0±27.0 pg/ml (Mean±SD) after CE administration and there were no significant differences among these groups. Estrogen receptor concentrations of endometrium of progestins or antiestrogen added groups were not changed, when compared with the CE alone group. There was also no relationship between the estrogen receptor concentrations and the histologic findings in the endometrium. This discrepancy may be chiefly due to the low dose of the progestins as compared with the CE dose. In view of the morphologic findings for the endometrium, this study suggests that opposed estrogen treatment with 19-nortestosterone derivatives provides the most satisfactory endometrial protection against hyperplasia.

Key words: Opposed estrogen treatment, Progestin.

(*Endocrine Journal* **41:** 161–169, 1994)

IT IS WELL KNOWN that postmenopausal estrogen replacement therapy alleviates climacteric symptoms. However, unopposed estrogen treatment increases the risk of endometrial cancer. Since progestin has been shown to prevent the development of endometrial hyperplasia and cancer, combined estrogen and progestin therapy is widely used for postmenopausal complaints. Depending on the various forms of their derivatives, progestins have androgenic and/or antiestrogenic effects. The only common effect ascribed to all progestins is the ability to induce the secretory phase in the estrogen-primed endometrium. However, the effect of progestins on the endometrium may be related to the qualitative difference in the metabolism of the progestin. This study is designed to evaluate the potential progestagenic and

Received: April 7, 1993
Accepted: December 17, 1993
Correspondence to: Dr. Takahiro KUMASAKA, Department of Obstetrics and Gynecology, Dokkyo University, Mibu, Tochigi 321–02, Japan

anti-estrogenic effects of some progestins on estrogen primed, ovariectomized rat endometrium.

Materials and Methods

As progestin of 19-nor-testosterone derivatives, Allylestenol (AE: Nihon Organon Tokyo), Norethisterone (NE: Shionogi Pharmac. Co. Osaka) and Danazol (DZ: Tokyo Tanabe Pharmac. Co. Tokyo); as 17α-hydroxyprogesterone derivatives, Dydrogesterone (DG: Daiichi-Seiyaku Co. Tokyo), Medroxyprogesterone acetate (MPA: Nihon Upjohn Limit. Tokyo) and Cyproterone acetate (CPA: Nihon Schering Co. Osaka); and as an anti-estrogenic derivative, Tamoxifen (TMX: I.C.I. Pharmac. Co. Osaka) were all examined for their effects on ovariectomized and conjugated equine estrogen (CE: Nihon Wyeth Co. Tokyo) treated rat endometrium, and estrogen receptor concentrations in the endometrium were measured. As the steroid solvent, Tween-80 (TW-80: Wako Pure Chemical Industries Ltd, Tokyo) was used. Four weeks after the ovariectomies, the rats were randomly divided into 7 groups, each group being composed of five rats. CE was dissolved at a ratio of 50 μg/0.5 m*l* in distilled water. Progestins and ethinyl estradiol (EE: Wako Pure Chemical Industries Ltd Tokyo) were dissolved at a ratio of 2.0 μg/0.5 m*l* in TW-80. As control groups, one group was given 50 μg/day of CE orally for 4 weeks, and the other 2.0 μg/day of EE in a similar way. As treated groups, the rats were to be given 50 μg/day of CE for 2 weeks and 2.0 μg/day of progestin or TMX with 50 μg/day of CE for 2 consecutive weeks (Fig. 1).

The rats were sacrificed with an overdose of ether and a histological examination of the endometrium was performed. Estradiol receptor concentrations in the endometrium were measured by radioligand assay.

The method for histological investigation: All the uteri of the rats in this study were fixed in 10% formalin immediately after resection. After sufficient fixation, six or seven tissue blocks for histological sections were obtained from each uterus (including the control cases), embedded in paraffin, and the sections were stained with hematoxylin eosin.

The method of estrogen receptor assay of the endometrium: The concentrations of cytosol estrogen receptors in the endometrium of the rats were measured by radioligand assay with Dextran coated charcol [1]. The flowchart of estrogen receptor analysis of the cytosolic estrogen receptor assay is shown in Fig. 2. The minimal amount of tissue required for the measurement of cytosolic receptor was 20 mg. The minimum detectable dose was 8 fmol/mg protein. A five-point Scatchard assay was performed with a concentration range for the radiolabelled estradiol (specific activity: 93 Ci/mmol) of 0.05 to 2 mmol/L. A 250 fold molar excess of unlabeled diethylstilbestrol was used in a parallel series of tubes to distinguish specific from total binding.

The maximum binding concentration was ob-

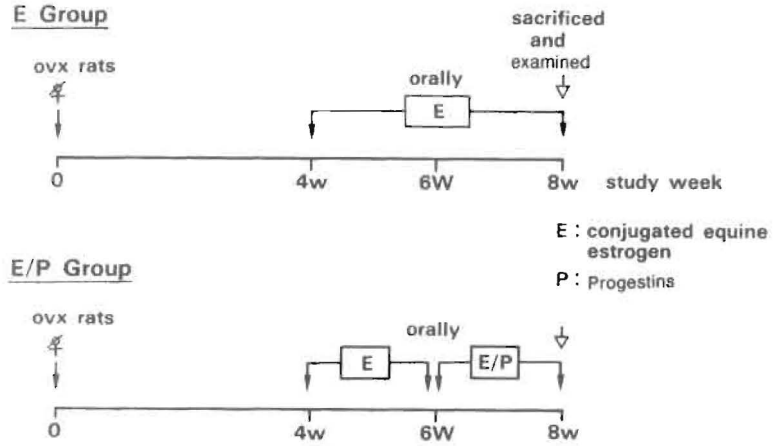

Fig. 1. Methods of CE and progestins treatment in ovariectomized rat.

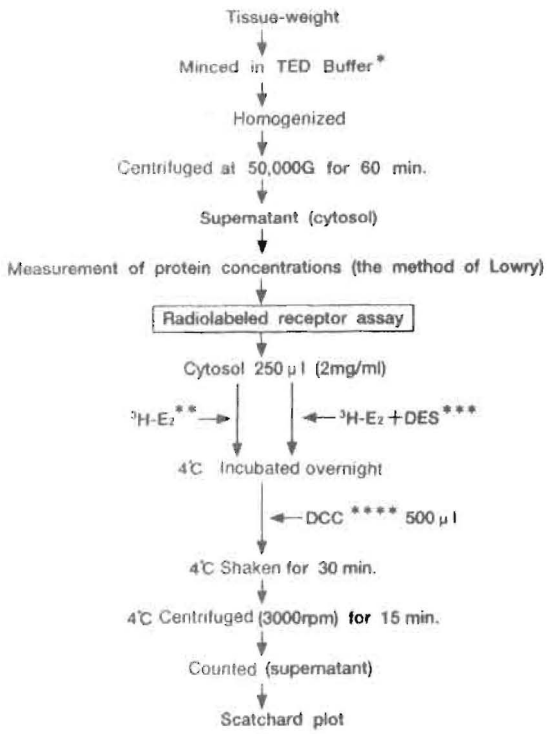

Fig. 2. The flowchart of cytosolic estrogen receptor assay. *, TED buffer: (10 mmol Tris-HCl, pH 7.4, 1.5 mmol EDTA, 1.0 mmol Dithiothreitol); **, ^{3}H-estradiol: (93 Ci/mmol NEN); ***, DES: Diethylstilbestrol; ****, DCC: Tris, Norit A, Dextran T. 70.

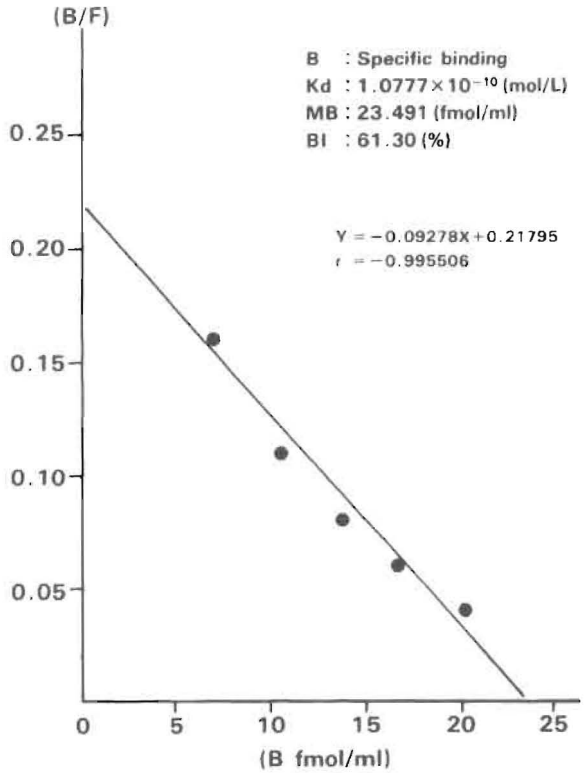

Fig. 3. Scatchard plot of estrogen receptor assay.

tained by Scatchard plot analysis (Fig. 3). An unpaired *t*-test was used for statistical analysis.

Assay of plasma estradiol and progesterone concentrations: The assay of plasma estradiol and progesterone concentrations was carried out by radioimmunoassay in a commercial laboratory (SRL. Co Tokyo).

Results

Histological findings

1) CE group: (positive control)

The uterine wall was moderately thickened. The endometrial glands consisted of large and high columnar epithelium with eosinophilic cytoplasm, showing secretory activity with marked subnuclear vacuolization. The glands also showed scattered squamous metaplasia replaced by nonkeratinizing squamous cells. Leukocytic infiltration was also seen in the thickened and edematous stroma (Fig. 4).

2) EE group: (positive control)

In the study of this group the uterine wall was the thickest, due to both hypertrophic endometrium and a thickened muscular layer.

The endometrial glands showed signs of marked hyperplasia quite like that in the CE group and their hyperplasia was more prominent than in the CE group. There were conspicuous secretory vacuolizations in both sub- and supra-nuclear cytoplasms of the endometrial glands. Scattered squamous metaplasia was also seen in the glands. In the stroma there was small vessel proliferation and leukocytic infiltration.

3) TW-80 group (negative control)

The uterus was small in gross appearance. Histologically the endometrium was thin and inactive without frank mitotic figures.

4) 19-Nortestosterone+CE group: AE, NE, DZ

In all of the cases in this group the uterine size was macroscopically small. The endometrium was thin and showed neither proliferation nor secretory activity (Fig. 5).

5) 17α-hydroxyprogesterone+CE group: DG,

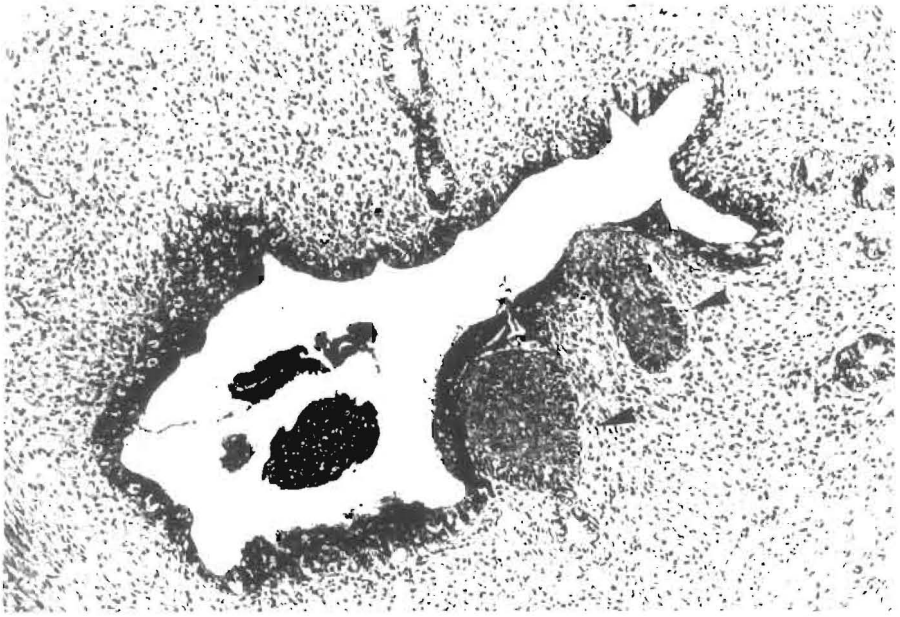

Fig. 4. Ovariectomized rat endometrium after CE only treatment (hematoxylin eosin stain, original magnification 25×). The endometrial glands consist of large and high columnar epithelium, showing secretory activity with marked subnuclear vacuolization and squamous metaplasia as indicated by the arrows.

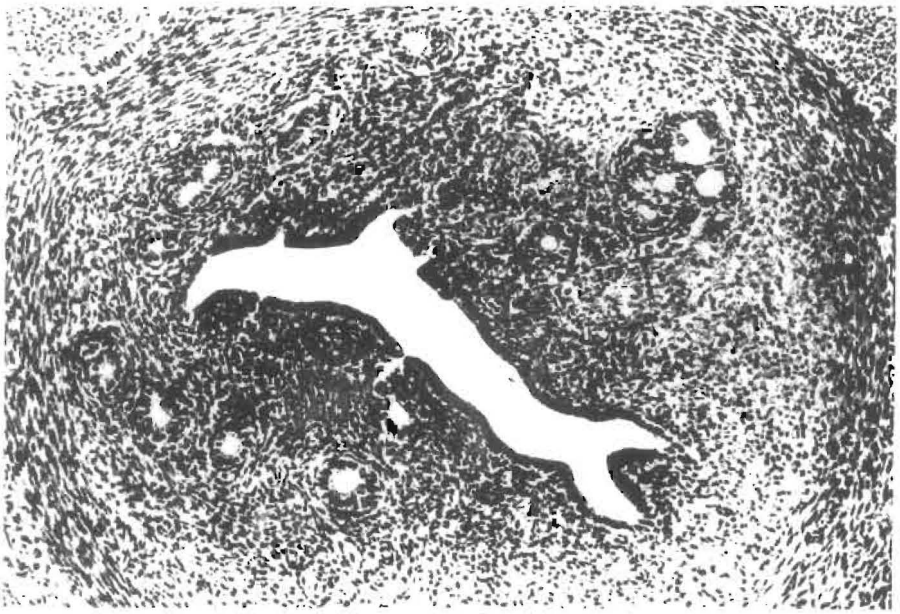

Fig. 5. Ovariectomized rat endometrium after CE and AE treatment (staining and magnification are the same as in Fig. 4), showing flattened or low columnar epithelium without secretory activity.

MPA, CPA

In both the DG and CPA groups the uterine wall was seen to be strongly thickened upon gross observation. Histologically, there was endometetrial hypertrophy of both the glands and the stroma. The glands showed increased secretory activity with dilated or tortuous ducts and high columnar epithelia especially in the DG group. The hyperplastic endometrium revealed atypical glandular proliferation in the CPA group. In both

Fig. 6. Ovariectomized rat endometrium after CE and DG treatment (staining and magnification are the same as in Fig. 4). The dilated or tortuous glands have many vacuoles, suggesting increased secretory activity. Each columnar epithelial cell is high, and mild decidual changes in the stroma are seen.

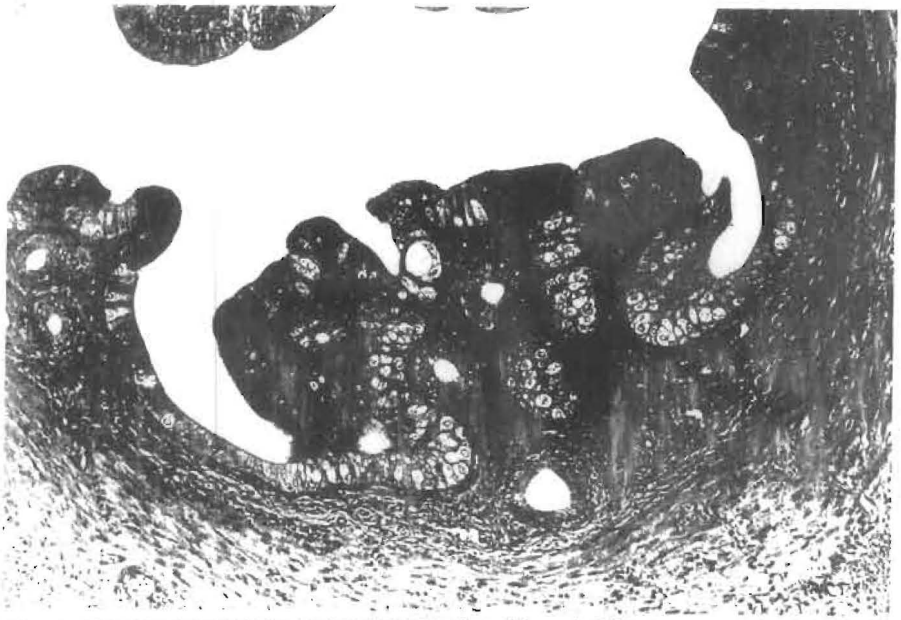

Fig. 7. Ovariectomized rat endometrium after CE and CPA treatment (staining and magnification are the same as Fig. 4). The hyperplastic endometrium reveals atypical glandular proliferation in this group. The epithelial cells of the crowded glands have round nuclei with a clear cytoplasmic halo.

groups in the thickened stroma there was edema with leukocytic infiltration and conspicuous proliferation of the small vessels. Decidual changes in the stroma were seen only in the DG group (Figs. 6, 7). In contrast to the two groups described above, the endometrial hyperplasia and angioectasia in the MPA group were slight, and no other changes could be seen.

6) TMX + CE group:

Although the uterine wall was not very thick in

this group, there was moderate proliferation of both glands and vessels in the endometrium. The glands consisted of large and high columnar epithelium without obvious secretory figures (Fig. 8). The previous data are summarized in Table 1.

Cytosolic estrogen receptor:

Figure 9 shows the effect of progestin on estrogen receptor concentrations in the endometrium of CE treated rats. The concentrations were increased rather more after NE and DZ treatment than after treatment with CE alone. But compared to the CE alone treated group, the DZ, AE, MPA and TMX groups had no significant change in concentrations.



Fig. 8. Ovariectomized rat endometrium after CE and TMX treatment (staining and magnification are the same as Fig. 4). There is moderate proliferation of glands consisting of large and high columnar epithelium.

Table 1. Histological findings of ovariectomized rat endometrium after CE and progestins or an antiestrogen administration

	19-Nortestosterone			17α-Hydroxyprogesterone					
	AE+CE	NE+CE	DZ+CE	DG+CE	MPA+CE	CPA+CE	TMX+CE	CE	EE
Vessels									
angioectasia/ proliferation	−	±	−	+~++	+	+++	+~++	++	++
Glands									
hyperplasia	−	−	−	+~++	±	+++	++	++	++
tortuous	−	−	−	++	±	+	+	+	+
secretory	−	−	−	++	−	+	±	++	++
Stroma									
edema	−	−	−	±	−	−	−	+	−
decidual	−	−	−	+	−	−	−	−	−
thick	−	−	−	+++	−	+++	+	++	+++
Sequamous *metaplasia*	−	−	−	−	−	−	−	+	+

AE, Allylestrenol; NE, Norethisterone; DZ, Danazol; DG, Dydrogesterone; MPA, Medroxyprogesterone acetate; CPA, Cyproterone acetate; TMX, Tamoxifen; CE, Conjugated equine estrogen; EE, Ethinyl estradiol.

Plasma estrogen levels:

The mean values for the plasma concentrations of estradiol were 82.0±27.0 pg/ml (mean±SD) when the rats were killed. There was no significant difference in plasma estrogen levels among the groups (Fig. 10).

Plasma progesterone levels:

Because of a cross-reaction between progesterone and TW-80 in our radioimmunoassay system, the measurement of plasma progesterone concentrations was impossible.

Discussion

There are many reports which indicate an increase in the incidence of hyperplasia and endometrial carcinoma in women treated with a relatively large dose of conjugated equine estrogens. Gelfand *et al.* [2] reported that endometrial hyperplasia was

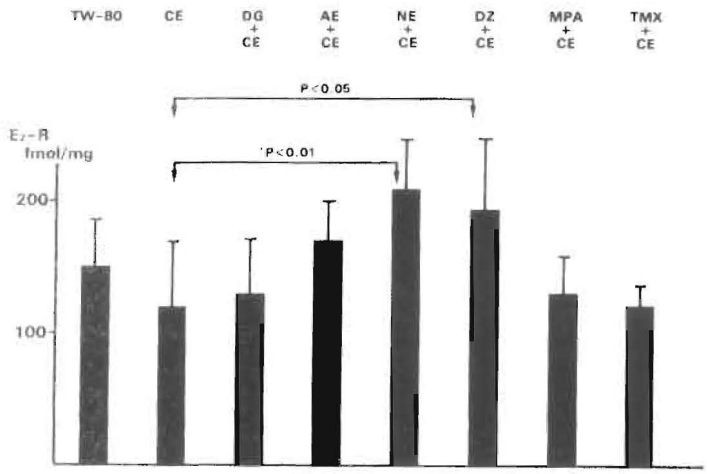

Fig. 9. Effect of progestins on estradiol receptor concentrations of ovariectomized rat endometrium (N: 5 in each group). TW-80, Tween-80; CE, Conjugated equine estrogen; DG, Dydrogesterone; AE, Allylestrenol; NE, Norethisterone; DZ, Danazol; MPA, Medroxyprogesterone acetate; TMX, Tamoxifen.

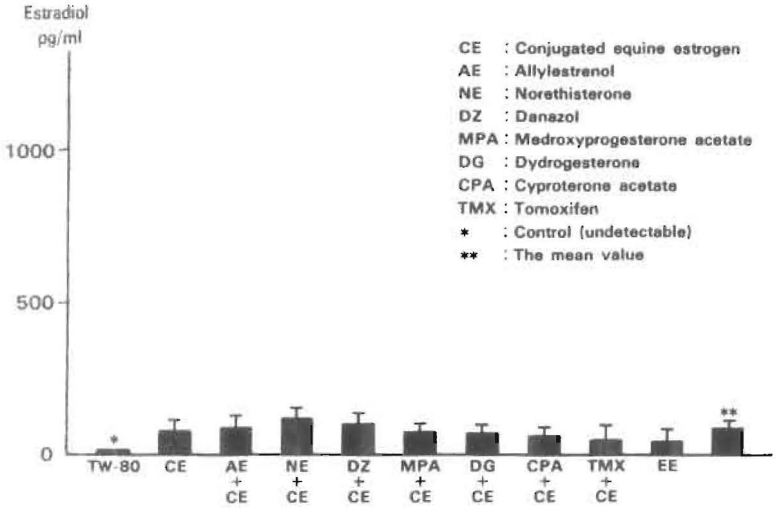

Fig. 10. Plasma estradiol concentrations in estrogens and progestins treated ovariectomized rat (N: 5 in each group).

considerably more frequent in patients who received CE or a placebo than in their counterparts treated with progestin. This prompted the addition of the estrogen-antagonist progestin to the estrogen replacement regimen to reduce the incidence of both hyperplasia and carcinoma of the endometrium. Although considerable information on progestin has been obtained, investigations are still being made to select the optimal dose of appropriate progestin for a treatment regimen. Some progestins have estrogenic properties, and these properties cannot be properly evaluated by using hormone responsive systems when the chosen endpoints are also sensitive to progestagenic activity.

Markiewicz *et al.* [3], using his newly developed *in vitro* method, reported that progesterone, MPA and DZ were found to be devoid of estrogen activity, but that Org OD-14, norethynodrel, gestrine (R2323), norethindrone (norethisterone) and dl-norgestrel provoked estrogenic activity, but in our experiment 19-nortestosterone derivatives did not show any estrogenic effect. This may be result from difference between *in vitro* and *in vivo* systems.

The type of estrogen used in our study was conjugated equine estrogen because of its frequent use in clinical treatment. Progestins which are usually administered orally are divided into 19-nortestosterone and 17α-hydroxyprogesterone derivatives according to their molecular structure. This study has shown that CE given without progestin is a very potent stimulator of rat endometorium, as in humans. The regimen of 50 μg/day of CE for 4 weeks was associated with hyperplasia in 100% of the rat endometorium.

Although it is unclear whether the concept and terminology regarding the morphologic spectrum of rat endometrial hyperplasia is the same as human endometrium, it has been shown that CE or EE given without progestin is a very potent stimulator of endometrium. None of the rats which received 19-nortestosterone derivatives (AE, NE, DZ) had hyperplasia, thickness of stroma or proliferation of vessels. On the other hand the prevention of endometrial hyperplasia, angioectasia and thickness of stroma seems to be weak when 17α-hydroxyprogesterone derivatives (DG, MPA, CPA) are used. Both DG and CPA were found to cause endometrial hypertrophy of both glands and stroma. Interestingly, the endometrium specimen of the CPA treated group showed more angioectasia, hyperplasia and thickened stroma than the other progestin treated groups. Because such findings were not reported in humans, this difference may therefore be attributable to the species.

Out of the progestin group in the 17α-hydroxyprogesterone derivatives, MPA had a rather preventive effect on angioectasia, hyperplasia and thickness of stroma. Our observations were in agreement with those of previous studies [2, 4, 5], in which MPA was introduced to prevent the development of hyperplasia caused by estrogen treatment. Brooks *et al.* [6] reported that MPA and NE were the least successful in suppressing stroma thickness, proliferation of glands and vascular dilatation. DZ worked better than these progestins in perimenopausal bleeding women. This suggests that the characteristic prevention of endometrial hyperplasia is related to the original molecular structure of the progestin derivatives. As a nonsteroidal antiestrogen, TMX is well known, and is used for pre- and postmenopausal patients with breast cancer. Gal *et al.* [7] reported that endometrial hyperplastic changes were found in 27% of patients who had received TMX therapy following a prospective study. In our study also, in the TMX group an estrogenic effect on rat endometrium failed to be prevented after CE treatment. These results indicate that TMX has a hyperplastic effect or non anti-estrogenic effect on the endometrium. In this study, we failed to demonstrate a reduction in estrogen receptor in any progestin or anti-estrogen groups. Although the reason for this discrepancy is unclear, Itoh [1] and Jänne *et al.* [9] reported that there was no correlation between serum estradiol/progesterone, LH and FSH levels and the endometrial estrogen/progesterone receptor concentrations in peri-menopausal women. Gibbons *et al.* [8] and Jänne *et al.* [9] showed that MPA, regardless of the dosage, was successful in reducing estradiol receptor concentrations to pretreatment levels, when only a low dose of CE was used. In this study, the regimen was performed as a single dose study. It may be considered that there was a dose imbalance between estrogen and progesterone which was necessary to reduce the endometrial estrogen receptor. This means that a higher dose of progestin could suppress the estrogen receptor to a low level. To summarize, although most progestins provided

endometrial protection against hyperplasia, the 19-nortestosterone group most satisfactorily prevented the endometrial hyperplasia caused by estrogen treatment. CPA and TMX do not seem to be useful for the prevention of endometrial hyperplasia.

References

1. Itoh E (1990) Measurement of estrogen receptor and progesterone receptor in human endometrium and endometrial carcinoma. *J Jpn Soc Cancer Ther* 25: 812–820 (In Japanese).
2. Gelfand M, Ferenczy A (1989) Prospective 1-year study of estrogen and progestin in postmenopausal women: Effects on the endometrium. *Obstet Gynecol* 74: 398–402.
3. Markiewicz L, Hochberg RB, Gurpid E (1992) Intrinsic estrogenicity of some progestagenic drugs. *J Steroid Biochem Mol Biol* 41: 53–58.
4. Ferenczy A, Gelfand M (1989) The biologic significance of cytologic atypia in progestogen-treated endometrial hyperplasia. *Am J Obstet Gynecol* 160: 126–131.
5. Lindahl B, Alm P, Fernö M, Norgren A (1990) Endometrial hyperplasia: A prospective randomized study of histology, tissue steroid receptors and plasma steroids after abrasio, with or without high dose gestagen treatment. *Anticancer Research* 10: 725–730.
6. Brooks P, Serden SP, Davos I (1991) Hormonal inhibition of the endometrium for resectoscopic endometrial ablation. *Am J Obstet Gynecol* 164: 1601–1608.
7. Gal D, Kopel S, Bashevkin M, Lebowicz J, Lev R, Tancer ML (1991) Oncogenic potential of tamoxifen on endometrial of postmenopausal women with breast cancer—preliminary report. *Gynecol Oncol* 42: 120–125.
8. Gibbons WE, Moyer LD, Lobo RA, Roy S, Michel DR (1986) Biochemical and histologic effects of sequential estrogen/progestogen therapy on endometrium of postmenopausal women. *Am J Obstet Gynecol* 154: 456–461.
9. Jänne O, Kauppila A, Kontula K, Syrjälä P, Vihko R (1979) Female sex steroid receptors in normal, hyperplastic and carcinomatous endometrium. The relationship to serum steroid hormones and gonadotropins and changes during medroxyprogesterone acetate administration. *Int J Cancer* 24: 545–554.